

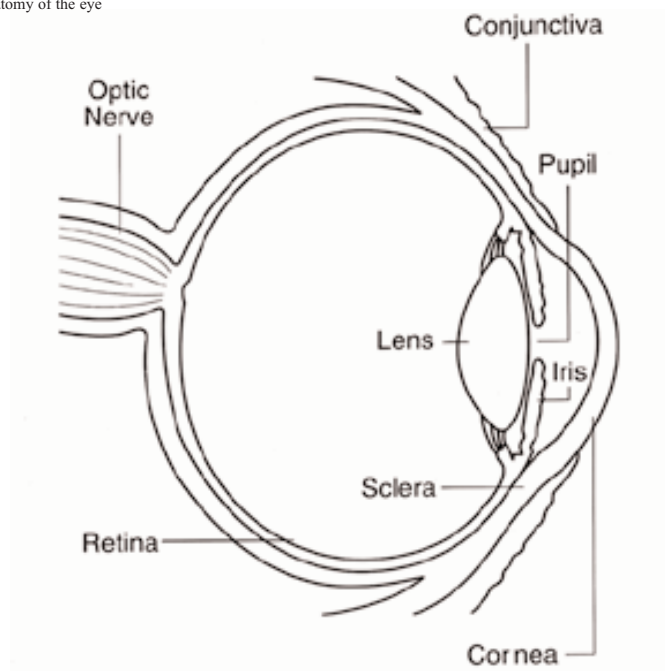
Refractive surgery techniques for vision correction

Visual acuity has been traditionally corrected by spectacles or contact lenses. However, the popularity of refractive surgery vision correction of vision has dramatically increased, and therefore there will be a commensurate increase in the number of pilots and applicants for pilot training who have undergone or thinking of undergoing such a procedure. This Briefing Leaflet sets out to explain the commonly used surgical techniques.

Anatomy of the eye

To understand the techniques it's a good idea to start with an explanation of the eye's anatomy. One-sixth of the outer layer of the eye bulges forward as the cornea, which is a transparent avascular dome in the middle of the outer surface of the eye. The anterior chamber is between the cornea and iris, and contains aqueous humor, which is responsible for ocular pressure. The iris is used for controlling the amount of light which enters the retina. The lens is behind the iris and is used for accommodation. Vitreous humor is a transparent, gelatinous mass between iris and retina. In the retina, light impulses are changed into electrical signals and then sent along the optic nerve to the occipital (posterior) lobe of the brain, which interprets these electrical signals as visual images.

Fig 1. The anatomy of the eye



The structure of the cornea

The cornea is composed, for the most part, of connective tissue with a thin layer of epithelium on the surface. Epithelium is the type of tissue that covers all free body surfaces.

The cornea is composed of 5 layers, from the front to the back:

1. epithelium
2. Bowman's (anterior limiting) membrane
3. stroma (substantia propria)
4. Descemet's (posterior limiting) membrane
5. endothelium (posterior epithelium)

The transparency of the cornea is due to the fact that it contains hardly any cells and no blood vessels. Nutrition and oxygen is provided by aqueous humor and the outside air by diffusion. Corneal wounds heal without scarring if the Bowman's membrane remains intact, otherwise scarring to some degree will appear.

Optics

Light waves from an object enter the eye first through the cornea, then through the pupil, lens and vitreous humor and produce an image on the retina. The light waves are converged first by the cornea (the primary and most powerful focusing structure) and then further by the lens. The lens is used for accommodation. In accommodation for near vision the curvature of the lens (and its refractive power) is increased to bend the light rays onto the retinal plane so that the image of the near point is sharp. In accommodation for distant vision the lens is more flat and light rays from distant object give a sharp image.

Myopia, hyperopia, and astigmatism

If the incoming light from a far away object focuses before it gets to the back of the eye, that eye's refractive error is called "myopia" (nearsightedness). It can be corrected by divergent lenses with minus diopters. If incoming light from something far away has not focused by the time it reaches the back of the eye, that eye's refractive error is "hyperopia" (farsightedness). It, in turn, can be corrected by convergent lenses with plus diopters. In the case of "astigmatism," one or more surfaces of the cornea or lens are not spherical but, rather, are cylindrical. As a result, there is no distinct point of focus inside the eye but, rather, a smeared or spread-out focus. Astigmatism is the most common refractive error.

Visual Acuity

Visual acuity is a measure of the resolving power of the eye. With adequate light, the normal eye should be able to discriminate two points when the light rays reaching the eye from them form an angle of 1 minute. The reciprocal value $1/\alpha$ represents the normal visual acuity, and in the normal eye it is around 1.

Clinical testing of visual acuity makes use of tables with large letters, the details of which, at the given distance are seen as subtending the angle of 1'. Visual acuity can be calculated from the actual distance/normal distance at which the letters can be recognised. For example, normally one should be able to recognize certain sized letter from certain distance, e.g. 3.3 m. If one is able to do so, the visual acuity is $3.3/3.3 = 1$. If, however, one barely recognise letter sized for e.g. 8.5 m, the visual acuity is $3.3/8.5 = 0.39$, since the normal eye would recognise the letter at 8.5 m.

Refractive Surgery

All the different refractive surgery techniques result in a change to the curvature of the cornea in order to produce a sharp image onto a retina. Refractive surgery is used for both myopic and hyperopic eyes, but is more commonly used for the correction of myopia, and in these operations the curvature of the cornea is decreased. There are several techniques available, and more are developed all the time. We will focus on the most common ones.

Radial keratotomy (RK)

Radial Keratotomy (RK) is described as "a surgical operation to improve myopia by changing the curve of the cornea over the pupil by making several deep incisions in the cornea in a radial or spoke-like pattern. The incisions are intended to flatten out the central cornea to correct the patient's vision." A series of cuts (usually 4 to 8) are made in the cornea with a scalpel, in a pattern that resembles a spoked wheel. These cuts are fairly deep, sometimes to 90% of the thickness of the cornea. As you can see from the diagram below, these "V" cuts cause the central cornea to relax or flatten and the peripheral cornea to steepen, reducing the dome of the central cornea with a resulting improvement in uncorrected vision.

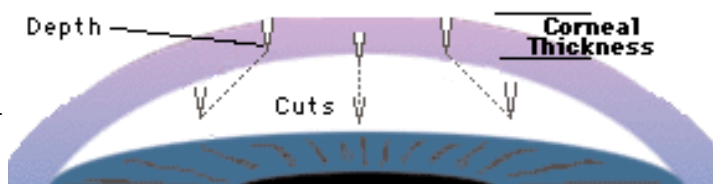


Fig 2. Radial keratotomy

Even with lasers and computers, the older "standard" type of RK has been found to have major shortcomings and limitations. Firstly, RK can only be used to correct low amounts of myopia. It cannot address the problems of hyperopia (farsightedness). The main drawback is the 90% thickness weakening of the cornea which frequently leads to progressive flattening of the cornea and increasing farsightedness.

Complications of the operation include fluctuating vision, a weakened cornea that is more vulnerable to rupture if hit directly, the possible need for additional refractive surgery; difficulty fitting contact lenses should they be required, and glare or starbursts around lights (haze). Due to these possible complications, RK is rarely used nowadays, but there are numerous patients who have undergone this operation.

Photoreactive keratectomy (PRK)

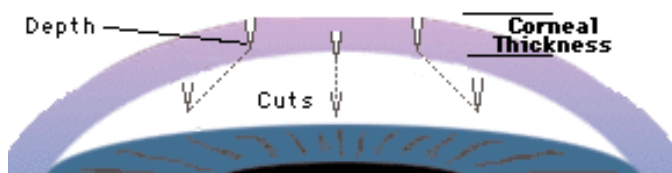


Fig 3. PRK in myopic eye.

Rather than making cuts in the cornea, the PRK process uses an excimer laser to sculpt an area 5 to 9 millimeters in diameter on the surface of the eye. As you can see from Figure 3, this process removes only 5-10% of the thickness of the cornea for mild to moderate myopia and up to 30% for extreme myopia. The major benefit of this procedure is that the integrity and the strength of the corneal dome is retained. The excimer laser is set at a wavelength of 193nm, which can remove a microscopic corneal cell layer without damaging any adjoining cells. This allows the practitioner to make extremely accurate and specific modifications to the cornea with little trauma to the eye.

This ability to sculpt, rather than cut, opens up the arena for treating additional vision conditions. At this stage, there are excimer laser machines that with a combination of masks and computer controls, can reliably treat myopia, hyperopia (Figure 4) and now astigmatism.



Fig 4. PRK in hyperopic eye.

Laser in situ keratomileus (LASIK)



Fig 5. Normal cornea.

Figure 5 shows a normal eye before any type of refractive procedure. The dark purple layer on the outer part of the cornea is called the epithelium. This protective outer layer is always removed when performing PRK but is left intact with LASIK. The cornea is sliced from the side by microkeratome to produce a flap (Figure 6). The result is a uniform flap with a hinge, that is rolled back to expose the inner layers of the cornea. With the flap folded back, the refractive correction on the inner layer of the cornea is done with excimer laser similar to PRK (Figure 7). When treatment is complete, the flap is repositioned in its original position and the procedure is complete. The eye has a natural suction facility that keeps the flap firmly in



Fig 6. Cutting the flap in LASIK.



Fig 7. Laser treatment in LASIK.

place at this time. Because very little of the epithelium has been disturbed, patients report a high comfort level after the procedure. Side-effects of the LASIK are overcorrection or undercorrection or irregular astigmatism (5-30%), corneal epithelial growth beneath the flap (1%), infection, best spectacle-corrected vision worse than 20/40 (<0.5%), corneal flap displacement (0.5%).

Laser Assisted Sub-Epithelial Keratomileus (LASEK)

In LASEK, the epithelium is detached by using a solution that weakens the epithelium and allows it to fold back into a flap after the edges are cut with a fine blade. The microkeratome used in LASIK is not used in LASEK. The LASEK flap only cuts the epithelium, not the lower stroma that the LASIK flap cuts. After the epithelium flap is moved out of the way, eximer laser energy is applied through the Bowman's layer and into the stroma to reshape the cornea. When the cornea has been reshaped by the laser, the epithelium flap is returned back to its original position. A contact lens is placed on the cornea as a bandage for several days to aid in the healing and the reduction of pain. The advantages of LASIK or LASEK over PRK are a reduction of postoperative discomfort, a decreased risk of infection, and decreased incidence of corneal haze.

Intracorneal ring (ICR)

The ICR is a corneal implant and is considered one of the newest developments in the area of refractive surgery. The ICR consists of small ring segments, which together have an inner diameter of 6.7mm. A small, approximately 1.8 mm long and 0.4 mm deep incision is placed in the cornea with a special diamond blade. Through this opening, two semicircular channels are prepared with a special, crescent-shaped instrument. The two-piece synthetic ring (each of the semicircular plastic pieces has an arch length of 150 degrees) is placed in the channels on the corneal periphery. The corneal centre is flattened between the two ring segments, which corrects the nearsightedness. The change in refractive power becomes noticeable within a few days. Due to the healing process, some fluctuations in vision may occur within the first 3 months after surgery but should decrease with time. Should the effect of treatment not be attained, the rings can be removed or replaced. One significant advantage of the ICR is that the central cornea is left intact and therefore there is no risk of scarring of the central cornea.



Fig 8. Intracorneal ring.

Intraocular lenses

Intraocular contact lens (ICL) is placed behind the iris in the posterior chamber of the eye. The design of the ICL is very similar to that of standard intraocular lenses used for cataract surgery. However, the ICL has been designed with forward vault to minimize contact with the central anterior capsule of the lens. Intraocular lenses can also be implanted in the anterior chamber of the eye.


Laser thermal keratoplasty

Laser thermal keratoplasty is a non-excimer laser refractive surgery. The office-based instrument applies two rings of laser energy to the midperiphery of the cornea. Each ring gently heats collagen in the cornea to change corneal shape. The application of energy is accomplished without physically contacting the cornea with instrumentation or other apparatus.

Conclusion

Although refractive error surgery procedures have been developed and the outcome of the procedures is good, every operation has its risks. Also, some of the techniques are new, and therefore there is no data available on the long-term results of these procedures. LASIK procedure is the most commonly used and long term results are good on this operation. One should have a thorough evaluation of the benefits and risks before undertaking such an operation.

The medical experts of IFALPA's Human Performance Committee do not recommend surgical procedures to correct visual acuity if medical certification can be achieved by non-surgical means.



IFALPA provides this data for information only, In all cases pilots should follow their company's guidance and procedures.

In the interests of flight safety, reproduction of this bulletin in whole or in part is encouraged. It may not be offered for sale or used commercially. All reprints must credit IFALPA.